

**HEMOPARASITES OF THE LAKE FROG
PELOPHYLAX RIDIBUNDUS (PALLAS, 1771) (RANIDAE, ANURA)
INHABITING RESERVOIRS OF THE NORTH-WESTERN CISCAUCASIA**

Tatyana Yu. Peskova, Olga N. Bachevskaya, and Gennady K. Plotnikov

*Kuban State University
149 Stavropolskaya Str., Krasnodar 350040, Russia
E-mail: peskova@kubannet.ru*

Received 20 February 2018, revised 11 April 2018, accepted 26 May 2018

The results of our study of the hemoparasites of the lake frog inhabiting the North-Western Ciscaucasian reservoirs are presented. It was found that the parasites are represented by three species, namely: the sporozoa *Hepatozoon magna* and *Dactylosoma ranarum*, and *Microfilaria*. Differences in the erythrocyte morphology of the lake frog when infected by sporozoa were identified. *Dactylosoma ranarum* does not alter the size of the erythrocytes affected. If there are *Hepatozoon magna* in the blood, the sizes of both the erythrocyte and its nucleus increase.

Key words: *Pelophylax ridibundus*, *Hepatozoon magna*, trophozoites, gamonts, *Dactylosoma ranarum*, meronts, North-Western Ciscaucasia.

DOI: <https://doi.org/10.18500/1814-6090-2018-16-3-4-146-152>

INTRODUCTION

As the lake frog's habitat includes two environments: aquatic and terrestrial, it can be both an intermediate and final host for a large number of blood parasites. In connection with this, the study of the species diversity of amphibian blood parasites as possible factors that may affect the number of these animals is of great interest (Frost, 2010). According to publications, the species that parasitize in the blood of lake frogs are trypanosomes, hemogregarins, microfilaria (Zmeev, 1935, 1936; Popov, 1951; Suzyumova, Grebennikova, 1974; Mikailov, Guseynov, 1979; Guseynov, 2002; Malysheva, 2009; Gaibova, Mamedova, 2010; Shiyan, 2011). Recently, hemogregarins of the *Lancestrel* genus have been detected in the blood of the lake frog (Mamedova, 2008). However, there are no data on the infection of the lake frog with blood parasites in our region.

The article presents the results of studies of blood parasites of lake frogs inhabiting two reservoirs of the North-Western Ciscaucasia.

MATERIAL AND METHODS

During the field season (from April to September 2017), 109 sexually mature males and females of the lake frog *Pelophylax ridibundus* (Pallas, 1771) were examined. Both reservoirs are permanent, flowing. The first reservoir is located in Krasnodar, near the old riverbed of Kuban river in the territory of the Krasny Kut forest park. 50 lake frogs were caught there. The second reservoir is in the Republic of Adygea, the Chibi Canal, in which 59 lake frogs were caught.

The captured animals were contained in aquariums for five days, then euthanized at the laboratory at the Department of Zoology of the Kuban State University. Their blood was taken from the heart ventricle by cutting. During the experiment, the rules of maintaining and processing experimental animals were complied with, including the experimental animal management and the animal sacrifice rules (Pravila provedeniya rabot, 2008).

The blood preparations prepared on degreased slides were anchored by 5-minute exposure in 95% ethanol, then air-dried and stained with azure-eosin for 40 minutes according to Romanovsky – Giemsa (pH = 7.2). Peripheral blood smears were examined with immersion (under a total magnification of 10x x100) of a Micros MC-209 light microscope.

When detecting hemoparasites during the blood smear analysis, we measured them according to the classical morphometric technique (Menshikov, 1999). We measured the size (length and width) of trophozoites, gamonts, and the nuclei of the sporozoa. As the main characteristics of infestation, we used infection extensity (IE) and infection intensity (II). The value of infection extensity (IE) characterizes the share of infected individuals as a percentage of the total number of examined frogs. II was determined by counting the number of parasites per 1000 erythrocytes in randomly selected fields of view of the microscope. In these fields, we counted the number of erythrocytes, in which various stages of parasite development were present and the number of extracellular parasites.

We measured the parasite cells and the host cells infected and free from parasites (in μm) and de-

terminated the shape index (*SI*), i.e. the length-to-width ratio of the cell. The reliability of differences in the size of different development stages of blood parasites, as well as blood cells of the lake frog, infected and free from parasites, was determined by the Student's *t*-test (t_{30} ; the significance level is 0.05) (Lakin, 1990).

The parasites' species were determined according to the determinants of K. M. Ryzhikov et al. (1980), R. S. Shultz, V. E. Gvozdev (1972), A. F. Alimov (2007). The systematics of hemoparasites is given in accordance with S. A. Karpov (2005).

RESULTS

We found three types of hemoparasites in the examined erythrocytes and in the blood plasma of lake frogs. These are sporozoa *Hepatozoon* sp. (Adeleorina, Apicomplexa, Alveolata): trophozoites and gamonts; sporozoa *Dactylosoma ranarum* (Adeleorina, Apicomplexa, Alveolata): meronts; as well as nematode *Microfilaria* sp. (Nematoda). The combined invasion with two or three parasites in one individual of lake frogs were not detected in both reservoirs.

Currently, there are two known species of the *Hepatozoon* genus infecting lake frogs: *H. magna* and *H. ridibundae*. *H. magna* was found in frogs inhabiting Kyrgyzstan (Malysheva, 2009). *H. ridibundae* was detected in frogs inhabiting Saudi Arabia (Shazly, 2003). The sporozoa discovered by us belong to the *Hepatozoon magna* species. *Hepatozoon magna* was found in 3 species of semi-terrestrial frogs and in 8 species of semi-aquatic frogs of South Africa (Netherlands et al., 2015). The lake frog is a semi-aquatic species too.

Hepatozoon magna were found both in and outside erythrocytes. Erythrocytes were infected with gamonts, while blood plasma with trophozoites. *Hepatozoon* gamonts are of elongated shape, have cells bent in the middle: the "tail" is pressed against the main body and is almost half as long. Trophozoites are more elongated, porrect, one end of the body is narrower, the other is wider and rounded (Figure 1).

The nuclei of infected erythrocytes were swollen, enlarged, pushed towards one of the cell's ends, their color is violet, but less saturated compared to the color of an unaffected erythrocyte's nucleus; there may be signs of polychromasia; the nuclei of some cells showed signs of lysis.

In erythrocytes infected with gamonts, the cell nucleus is pushed towards one of the cell's poles (Figure 1A). We found only a few cells, in which the nucleus was in the center and the parasite was pushed towards the cell's edge (Figure 1C). The front end of the gamonts is somewhat wider than the rear end. The parasite's cytoplasm was from bluish to lilac; in the

center there is a lilac- to crimson-colored nucleus (Figure 1B).

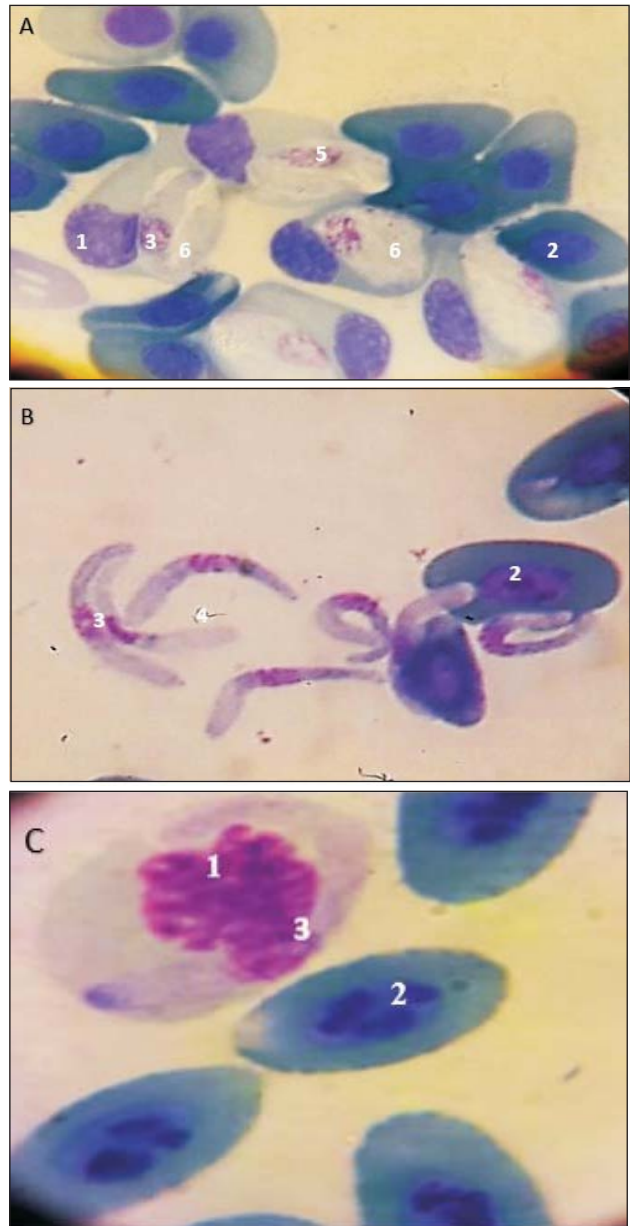


Fig. 1. Stages of *Hepatozoon magna* development (A, B, C): 1 – nucleus of the infected erythrocyte; 2 – nucleus of the uninfected erythrocyte; 3 – nucleus of the trophozoite; 4 – a free trophozoite; 5 – gamont; 6 – endoglobular trophozoite (photo by O. N. Bachevskaya)

Such indicators as the width of the gamont, the length and width of the gamont nuclei, and the length of the trophozoite nuclei of *Hepatozoon magna* are significantly different. All these parameters are greater in parasites from the blood of lake frogs caught in Chibi Canal. Infected erythrocytes also differ by the cell and nucleus widths. At the same time, the size of the erythrocyte itself are higher in the blood of frogs

from Krasny Kut, and the size of the erythrocyte nucleus is higher in the blood of frogs from Chibi Canal. As for uninfected erythrocytes, the cell and its nucleus are larger in frogs from Chibi Canal. *Hepatozoon* sp. found in toads in three populations from Africa also showed significant between-population differences in morphology of gamonts (Netherlands et al., 2014).

The intensity of infection with gamonts *Hepatozoon magna* in both reservoirs was validly higher than with trophozoites ($t_{st} = 2.44$ for frogs from Krasny Kut and $t_{st} = 12.34$ for frogs from Chibi Canal). In addition, the trophozoite and gamont infection intensity is higher in frogs from Krasny Kut reservoir ($t_{st} = 3.02$ and 2.04 , respectively). In South Africa *Hepatozoon* intensity across frog species ($\chi^2 = 17.683$, $P = 0.028$), across families ($\chi^2 = 11.717$, $P = 0.006$), and across the different habitat types ($\chi^2 = 7.227$, $P = 0.007$) showed a significant difference (Netherlands et al., 2015).

In the blood smears of the examined frogs from both biotopes, another species of sporozoa was identified. Its cells are oval, round, or lobate; their cytoplasm does not stain and contains chromatin grains (Figure 2). They have a different effect on the frogs' erythrocytes. These intra-erythrocyte parasites do not change the shape of the erythrocyte's nucleus and its localization in the cell, as well as the size of the erythrocyte. This parasite was identified as sporozoa *Dactylosoma ranarum* (Miyata, 1976; Malysheva, 2009). It is known that *Dactylosoma* spp. was found only in one species of amphibian of South Africa – semi-aquatic frogs *Ptychadena anchietae* (Netherlands et al., 2015).

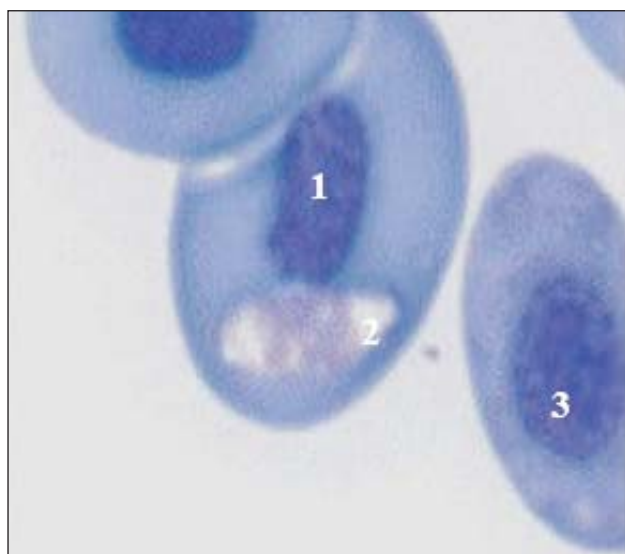


Fig. 2. Stages of *Dactylosoma ranarum* development (Meront): 1 – nucleus of the infected erythrocyte; 2 – meront of *Dactylosoma ranarum*; 3 – nucleus of the uninfected erythrocyte (photo by O. N. Bachevskaya)

The discovered larvae of microfilaria in both reservoirs had the following dimensions: $14.2 \pm 2.61 \times 4.16 \pm 0.03 \mu\text{m}$. The cytoplasm is colored from pale to rich lilac; the body is oblong, sometimes curved. Microfilaria were outside erythrocytes of the lake frog (Figure 3). Microfilaria were found in frogs' blood in many regions. We were unable to establish a more precise taxonomy of the parasite, as because of a rather large size, many of the larvae in the peripheral blood smears were damaged.

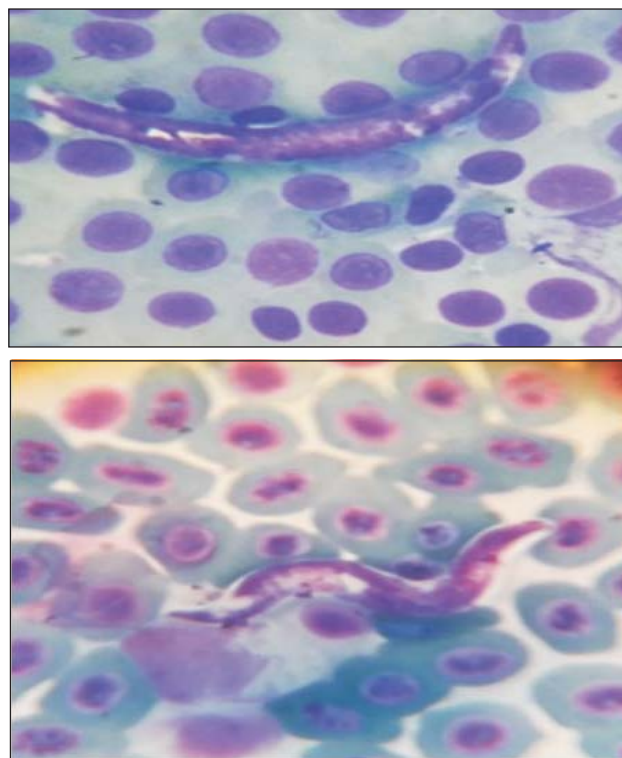


Fig. 3. Microfilaria in the lake frog's peripheral blood smears (photo by O. N. Bachevskaya)

Table 1 provides information on the infection of lake frogs from two reservoirs with these parasites.

A comparison of the intensity of infection with intra-erythrocytic stages of two sporozoa showed the existence of valid differences. The population of *Dactylosoma ranarum* meronts significantly exceeds the number of *Hepatozoon magna* gamonts in both reservoirs ($t_{st} = 2.77$ and 2.51 for Krasny Kut and Chibi Canal, respectively). There are no significant differences in the intensity of invasion between *Dactylosoma ranarum* meronts and *Hepatozoon magna* trophozoites. The intensity and extensity of infection with *Microfilaria* sp. is less than that with sporozoa.

The infection extensity of *Dactylosoma ranarum* is about twice as large as the infection extensity of *Hepatozoon magna* trophozoites. However, if we consider the infection extensity of *Hepatozoon magna*

HEMOPARASITES OF THE LAKE FROG

Table 1. Main indices of blood-parasite infection of the lake frog's erythrocytes

Reservoir	Infection intensity, qty	Infection extensity, %	Shape index
<i>Hepatozoon magna</i> , trophozoites			
Krasny Kut	$\frac{2-20}{10.8 \pm 1.24}$	12.0	9.7±0.36
Chibi Canal	$\frac{3-34}{17.3 \pm 1.76}$	17.0	10.1±0.75
<i>Hepatozoon magna</i> , gamonts			
Krasny Kut	$\frac{4-10}{7.0 \pm 0.94}$	2.0	2.3±0.07
Chibi Canal	$\frac{2-12}{5.2 \pm 1.08}$	10.2	2.3±0.04
<i>Dactylosoma ranarum</i> , meronts			
Krasny Kut	$\frac{3-48}{15.3 \pm 2.85}$	24.0	1.5±0.14
Chibi Canal	$\frac{2-46}{14.1 \pm 3.38}$	32.2	1.3±0.06
<i>Microfilaria</i> sp.			
Krasny Kut	$\frac{3-5}{4.3 \pm 1.06}$	6.0	–
Chibi Canal	$\frac{3-6}{4.5 \pm 1.44}$	3.4	–

without taking into account the stage of this parasite, the data the difference in the level of extensity of two sporozoa is less in 1,7 times (for lake frogs from Kras-

ny Kut) and in 1,2 times (for lake frogs from Chibi Canal).

The sporozoa cell and nuclei size, as well as those of infected and uninfected erythrocytes of lake frogs from the two reservoirs, are provided in Tables 2 and 3. Table 4 shows the Student's test values, when similar indicators of lake frogs from the two reservoirs were compared.

DISCUSSION

The infection intensity in the blood of lake frogs from the reservoirs in Azerbaijan with *Hepatozoon magna* gamonts is from 3 to 18 and with trophozoites is from 1 to 3 (Gaibova, Mamedova, 2010). A comparison with the data obtained by us showed that the gamont infection intensities in the reservoirs of Azerbaijan and North-West Ciscaucasia do not differ, and the intensity of trophozoite infection in reservoirs of the North-Western Caucasus is higher.

The extensity of infection with *Hepatozoon magna* in various reservoirs in Azerbaijan was 9 – 60% (Gaibova, Mamedova, 2010), i.e. higher than in reservoirs in our region. According to M. A. Guseynov (2002), the extensity of *Hepatozoon magna* infection varies in reservoirs of various types: in Azerbaijan, it is 0 – 27.8% in rivers, 0 – 10.3% in lakes, and 0 – 33.3% in water-storage reservoirs. Our data obtained by studying frogs from flowing water bodies correspond to these values.

Table 2. Morphometric characteristics of *Hepatozoon magna* blood parasites and erythrocytes of the lake frog

The parasite's and host's cells (n = 100)	Parasite sampling sites					
	Krasny Kut (7/50) *			Chibi Canal (16/59) *		
	Length, μm	Width, μm	Shape index	Length, μm	Width, μm	Shape index
Gamont	16.3±0.28	7.1±0.16	2.3±0.07	17.2±0.58	7.6±0.12	2.3±0.04
Gamont nucleus	3.5±0.09	3.1±0.07	1.1±0.05	4.0±0.22	3.6±0.09	1.1±0.16
Trophozoite	28.9±1.13	3.0±0.09	9.7±0.36	31.0±0.71	3.1±0.22	10.1±0.75
Trophozoite nucleus	4.8±0.25	3.1±0.10	1.5±0.08	6.2±0.28	2.8±0.19	2.2±0.07
Infected erythrocyte	25.1±0.54	16.3±0.36	1.5±0.04	26.4±0.54	14.8±0.41	1.8±0.07
Nucleus of an infected erythrocyte	14.4±0.43	7.7±0.21	1.9±0.10	15.3±0.46	8.5±0.37	1.8±0.09
Uninfected erythrocyte	23.2±0.35	12.0±0.22	1.9±0.04	24.5±0.13	11.6±0.24	2.1±0.01
Nucleus of an uninfected erythrocyte	8.8 ±0.11	5.4±0.13	1.7±0.05	9.6±0.17	6.1±0.16	1.6±0.06

Note. * The ratio of the numbers of infected cells and examined hosts is provided.

Table 3. Morphometric characteristics of *Dactylosoma ranarum* blood parasites in the lake frog

The parasite's and host's cells (n = 100)	Parasite sampling sites					
	Krasny Kut (12/50) *			Chibi Canal (19/59) *		
	Length, μm	Width, μm	Shape index	Length, μm	Width, μm	Shape index
Parasite	6.8±0.27	4.5±0.32	1.5±0.14	7.7±0.43	6.1±0.60	1.3±0.06
Infected erythrocyte	23.7±0.57	13.6±0.47	1.7±0.03	24.3±1.01	13.6±0.77	1.8±0.12
The nucleus of infected erythrocytes	8.1±0.15	4.9±0.06	1.6±0.02	8.3±0.27	5.1±0.17	1.6±0.06
Uninfected erythrocyte	22.7±0.26	12.3±0.21	1.8±0.03	22.8±0.28	12.4±0.26	1.8±0.05
The nucleus of uninfected erythrocytes	8.1±0.14	5.1±0.07	1.6±0.02	8.1±0.15	5.1±0.08	1.6±0.04

Note. * The ratio of the numbers of infected cells and examined hosts is provided.

Table 4. Student's test values at pairwise comparison of the morphometric characteristics of blood parasites in lake frogs from two reservoirs

Parasite type	Cell type	Cell length	Cell width
<i>Hepatozoon magna</i>	Gamont	1.40	2.25*
	Nucleus of the gamont	2.40*	4.12*
	Trophozoite	1.56	0.42
	Nucleus of the trophozoite	3.76*	1.40
	Infected erythrocyte	1.69	2.79*
	Nucleus of an infected erythrocyte	1.46	2.00*
	Uninfected erythrocyte	3.51*	1.23
	Nucleus of an uninfected erythrocyte	3.90*	3.98*
<i>Dactylosoma ranarum</i>	Parasite	1.79	3.30*
	Infected erythrocyte	0.47	0.03
	The nucleus of infected erythrocytes	0.74	0.77
	Uninfected erythrocyte	0.39	0.24
	The nucleus of uninfected erythrocytes	0.15	0.38

Note. * Valid differences for the 5% significance level.

The intensity of infection with *Dactylosoma ranarum* sporozoa in the reservoirs of Azerbaijan is 6–10% (Gaibova, Mamedova, 2010), which is less than in frogs from the reservoirs studied by us. According to other data (Guseynov, 2002), *Dactylosoma ranarum* was not found at all in any of 577 examined lake frogs.

In South Africa *Hepatozoon* sp. accounted for most of the infections at 59/436 (14%), microfilaria infections accounted for 2/436 (0.5%) and *Dactylosoma* sp. accounted for 13/436 (3%) of the overall prevalence respectively (Netherlands et al., 2015).

E. A. Sils (2008) believes that the immune processes in lake frogs inhabiting urbanized ecosystems enhance, the protective function of blood increases, which leads to a decrease in the intensity and extensity of blood-parasite infection. The scale of these processes depends on the level of the area urbanization. Based on this premise, we can suggest the same level of anthropogenic impact on the reservoirs studied by us.

We did not find any differences in the shape index of both *Hepatozoon magna* gamonts and trophozoites in the blood of lake frogs when compared frogs from the two reservoirs. For frogs from the reservoirs in Azerbaijan, gamonts and trophozoites have the same cell size as those known from publications (Gaibova, Mamedova, 2010). The shape index of *Dactylosoma ranarum* meronts in frogs from reservoirs of the Western Ciscaucasia is lower than that of frogs from Azerbaijan.

A comparison of the linear dimensions of erythrocytes infected and uninfected with *Hepatozoon*

magna in the blood of lake frogs from the same reservoir shows significant differences in all indicators; the infected erythrocyte and its nucleus are larger than the uninfected one. We may say that the sizes of gamont and its nucleus of *Hepatozoon* sp. from these species of African bufonids are larger than the ones we determined – 22.5 (21.2 – 26.6) × 8.2 (7.7 – 9.1) μm and 4.3 (4.1 – 4.6) × 4.5 (4.3 – 4.8) μm respectively (Netherlands et al., 2014).

Analysis of the morphometric characteristics of unaffected frog erythrocytes and their SI showed no significant differences in the individuals from two biotopes, where *Hepatozoon* was found. When comparing the morphometric parameters of parasitized erythrocytes the significant increase by 7.8% of length and 27.8% ($P < 0.001$) of width was found, but the SI of red cells was less than 15.25% ($P < 0.001$) (Korzh, Zadorozhnyaya, 2013).

An analysis of the linear dimensions of *Dactylosoma ranarum*, as well as of its infected erythrocytes, showed a difference only by one parameter: the width of the sporozoa cell. The size of an infected and an uninfected erythrocytes of lake frogs from both reservoirs are not validly different.

CONCLUSION

In the two examined populations of lake frogs, the observed species diversity of the blood parasites decreased to three species. In amphibians, we did not detect trypanosomes and some sporozoa, which are regularly detected by researchers in frogs in other regions.

The obtained data on the intensity and extensity of infection with the found blood parasites, as well as on the morphometry of the parasite cells and erythrocytes of the lake frog, show the presence of both interpopulation differences of these indicators within the same region and interregional differences.

The intensity and extensity of infection of microfilaria is less than these characteristics of sporozoa in blood of lake frogs from both reservoirs.

REFERENCES

- Alimov A. F. *Protists*. Saint Petersburg, Nauka Publ., 2007, part 2, pp. 194–195 (in Russian).
- Frost D. R. *Amphibian Species of the World: an online reference*, 2010. Available at: <http://research.amnh.org/vz/herpetology/amphibia> (accessed 24 January 2018).
- Gaibova G. D., Mamedova S. O. Blood parasites of the lake frog *Pelophylax ridibundus* from the reservoirs in Azerbaijan. *Visnyk of Karazin Kharkiv National University, Ser. Biology*, 2010, iss. 12, pp. 54–60 (in Russian).
- Guseynov M. A. Blood parasites of the lake frog (*Rana ridibunda* Pall.) of the basin of the middle part of the Kura river in Azerbaijan. Physico-geographical characte-

ristic of the studied reservoirs. *Bilgi*, 2002, iss. 2, pp. 35–39 (in Russian).

Karpov S. A. *System of Protozoa: History and Modernity*. Saint Petersburg, Tessa Publ., 2005. 72 p. (in Russian).

Korz A. P., Zadorozhnyaya V. Y. The biological characteristics of representatives of the genus *Hepatozoon* (Apicomplexa, Adeleorina) in the marsh frog (*Pelophylax ridibundus*) separate populations of Zaporizhzhya region. *Vestnik zoologii*, 2013, vol. 47, no. 2, pp. 34–39 (in Russian).

Lakin G. F. *Biometrics*. Moscow, Nauka Publ., 1990. 352 p. (in Russian).

Malysheva M. H. About the fauna of the blood parasites of tailless amphibians (Anura) in Kyrgyzstan. *Parazitologiya*, 2009, iss. 1, pp. 33–45 (in Russian).

Mamedova S. O. The coccidia of certain amphibians and reptiles in Azerbaijan. In: *Biodiversity and Ecology of Parasites of Terrestrial and Aquatic Cenoses*. Moscow, Center of Parasitology of IPEE, 2008, pp. 211–214 (in Russian).

Menshikov V. V. *Clinical Laboratory Analytics. Vol. 2. Individual analytical technologies in the clinical laboratory*. Moscow, Medizdat Publ., 1999. 352 p. (in Russian).

Mikhailov T. K., Guseynov M. A. About the study of blood parasites of lake frogs (*Rana ridibunda* Pall.) in the Devechi lagoon of the Caspian Sea. *Herald of the Academy of Science of the Azerbaijan SSR, Ser. Biological Science*, 1979, no. 1, pp. 70–72 (in Russian).

Miyata A. Anuran haemoprotozoa found in the vicinity of Nagasaki city. 2. *Dactylosoma ranarum* (Kruse, 1890). *Tropical Medicine*, 1976, vol. 18, no. 3, pp. 135–141.

Netherlands E. C., Cook C. A., Kruger D. J. D., du Preez L. H., Smit N. J. Biodiversity of frog haemoparasites from sub-tropical northern KwaZulu-Natal, South Africa. *International J. for Parasitology: Parasites and Wildlife*, 2015, vol. 4, pp. 135–141.

Netherlands E. C., Cook C. A., Smit N. J. Hepatozoon species (Adeleorina: Hepatozoidae) of African bufonids, with morphological description and molecular diagnosis of *Hepatozoon ixoxo* sp. parasitising three *Amietophrynus* species (Anura: Bufonidae). *Parasites and Vectors*, 2014, vol. 7, no. 1, pp. 552. DOI: <https://doi.org/10.1186/s13071-014-0552-0>

Popov P. P. Type: Protozoa. In: *The Animal World of Azerbaijan*. Baku, Academy of Sciences of Azerbaijani SSR Publ., 1951, pp. 525–543 (in Russian).

Ryzhikov K. M., Sharpilo V. P., Shevchenko N. N. *Helminths of amphibians of the USSR fauna*. Moscow, Nauka Publ., 1980. 275 p. (in Russian).

Sils E. A. The comparative analysis of hematological parameters of the urban populations of moor frogs (*Rana arvalis* Nilsson, 1842) and lake frogs (*Rana ridibunda* Pallas, 1771). *Vestnik of the Orenburg State University*, 2008, no. 10 (92), pp. 230–235 (in Russian).

Shazly A. M. Erythrocytic merogonic stages of *Hepatozoon ridibundae* sp. nov. infecting the Arabian ranid frogs, *Rana ridibunda* in Saudia Arabia with reflections on the haemogregarine complex. *J. of the Egyptian Society of Parasitology*, 2003, vol. 33, no. 2, pp. 497–516.

Shiyana A. A. *Ekologicheskaya kharakteristika ozernoy lyagushki (Rana ridibunda Pall.) pri obitanii na polyakh filtratsii sakharnykh zavodov [The environmental characteristic of the lake frog (Rana ridibunda Pal.) inhabiting the sugar plants' filtration fields]*. Thesis Diss. Cand. Sci. (Biol.). Saratov, 2011. 21 p. (in Russian).

Shultz R. S., Gvozdev V. E. *Basic Concepts of General Helminthology*. Moscow, Nauka Publ., 1972, vol. 2, pp. 515–516 (in Russian).

Suzyumova L. M., Grebennikova S. I. The features of hemoparasitic invasion in the lake frog. In: *The information materials of the Institute of Plant and Animal Ecology*. Sverdlovsk, 1974, vol. 2, pp. 18–19 (in Russian).

Pravila provedeniya rabot s ispolzovaniyem eksperimentalnykh zhitovnykh [The rules of processing experimental animals. Animals], 2008. Available at: <https://docplayer.ru/56350656-Pravila-provedeniya-rabot-s-ispolzovaniem-eksperimentalnyh-zhitovnyh.html> (accessed 20 September 2017) (in Russian).

Zmeev G. Ya. Hemoparasites of wild vertebrates in Tajikistan. *Proceedings of the Tajik Base of the Academy of Sciences of the USSR*, 1935, vol. 5, pp. 75–93 (in Russian).

Zmeev G. Ya. About the fauna of hemoparasites of wild vertebrates inhabiting certain southern regions of Tajikistan. *Proceedings of the Tajik Base Academy of Sciences of the USSR*, 1936, vol. 6, pp. 249–266 (in Russian).

Cite this article as:

Peskova T. Yu., Bachevskaya O. N., Plotnikov G. K. Hemoparasites of the Lake Frog *Pelophylax ridibundus* (Pallas, 1771) (Ranidae, Anura) Inhabiting Reservoirs of the North-Western Ciscaucasia. *Current Studies in Herpetology*, 2018, vol. 18, iss. 3–4, pp. 146–152 (in Russian). DOI: <https://doi.org/10.18500/1814-6090-2018-18-3-4-146-152>

**ГЕМОПАРАЗИТЫ ОЗЁРНОЙ ЛЯГУШКИ *PELOPHYLAX RIDIBUNDUS* (PALLAS, 1771)
(RANIDAE, ANURA) ИЗ ВОДОЁМОВ СЕВЕРО-ЗАПАДНОГО ПРЕДКАВКАЗЬЯ**

Т. Ю. Пескова, О. Н. Бачевская, Г. К. Плотников

*Кубанский государственный университет
Россия, 350040, Краснодар, Ставропольская, 149
E-mail: peskova@kubannet.ru*

Поступила в редакцию 20.02.2018, после доработки 11.04.2018, принята 26.05.2018

Приведены результаты исследования гемопаразитов озёрной лягушки из водоёмов Северо-Западного Предкавказья. Установлено, что видовой состав паразитов представлен тремя видами – это споровики *Hepatozoon magna*, *Dactylosoma ranarum* и микрофилярия. Определены различия морфологии эритроцитов озёрной лягушки при поражении споровиками. *Dactylosoma ranarum* не изменяет размеры пораженных эритроцитов. Если в крови имеются *Hepatozoon magna*, то увеличиваются размеры как самого эритроцита озёрной лягушки, так и его ядра.

Ключевые слова: *Pelophylax ridibundus*, *Hepatozoon magna*, трофозоиты, гамонты, *Dactylosoma ranarum*, меронты, северо-западное Предкавказье.

DOI: <https://doi.org/10.18500/1814-6090-2018-18-3-4-146-152>

Образец для цитирования:

Peskova T. Yu., Bachevskaya O. N., Plotnikov G. 2018. K. Hemoparasites of the Lake Frog *Pelophylax ridibundus* (Pallas, 1771) (Ranidae, Anura) Inhabiting Reservoirs of the North-Western Ciscaucasia [*Пескова Т. Ю., Бачевская О. Н., Плотников Г. К.* 2018. Гемопаразиты озёрной лягушки *Pelophylax ridibundus* (Pallas, 1771) (Ranidae, Anura) из водоёмов Северо-Западного Предкавказья] // Современная герпетология. Т. 18, вып. 3/4. С. 146– 152. DOI: <https://doi.org/10.18500/1814-6090-2018-18-3-4-146-152>
